HUMAN NANOPHYETIASIS: TRANSMISSION BY HANDLING NATURALLY INFECTED COHO SALMON (*ONCORHYNCHUS KISUTCH*)

LEE W. HARRELL and THOMAS L. DEARDORFF

Reprinted for private circulation from
THE JOURNAL OF INFECTIOUS DISEASES
Vol. 161, No. 1, January 1990

PRINTED IN U.S.A.

Human Nanophyetiasis: Transmission by Handling Naturally Infected Coho Salmon (*Oncorhynchus kisutch*)

Lee W. Harrell and Thomas L. Deardorff

From the National Marine Fisheries Service, Manchester (Washington) Marine Experimental Station, and the Fishery Research Branch, US Food and Drug Administration, Dauphin Island, Alabama

The first US case of human nanophyetiasis that does not involve ingestion of raw or undercooked salmonid fishes is reported. The patient worked with highly infected fish. Hand contamination with the infectious metacercariae of the digenetic trematode *Nanophyetus salmincola* (family Troglotrematidae) occurred during the handling of fresh-killed, juvenile coho salmon, *Oncorhynchus kisutch*. Diagnosis of nanophyetiasis was based on the clinical findings of chronic diarrhea, nausea, abdominal discomfort, and a peripheral blood eosinophilia of 43% and was confirmed on finding characteristic bipolar eggs in a stool specimen. The patient rarely ate seafood products and never ate raw or cold smoked fish. He responded favorably to praziquantel and was asymptomatic after therapy.

Although the potential for human infection with the parasitic trematode *Nanophyetus salmincola salmincola* (family Troglotrematidae) was demonstrated in 1956 when a researcher experimentally infected himself [1], the first naturally acquired human intestinal infections in the USA were only recently documented [2]. In that report it was shown that at least 8 of 10 infections were associated with digenetic trematodes transmitted by incompletely cooked or smoked salmonid fishes (Pacific salmon, *Oncorhynchus* species, and steelhead trout, *Oncorhynchus mykiss* [formerly *Salmo gairdneri*]). Subsequently, nine additional cases were reported from the same geographic area and the transmission in eight cases was linked to ingestion of salmonid fishes [3]. We report a patient who was infected with *N. salmincola* after handling naturally infected Pacific salmon. The symptoms were typical of nanophyetiasis.

Case Report

A 19-year-old man complained of flu-like symptoms of malaise, intermittent diarrhea, and general abdominal discomfort, periodically associated with nausea and vomiting. The patient had become aware of these symptoms ~2 months before seeking medical attention. On examination, hematologic findings revealed 43% eosinophilia. A stool specimen was positive for the bipolar eggs of *N. salmincola* (figure 1).

The patient was a biologic technician conducting research on the prevalence and intensity of *N. salmincola* in coho salmon, *Oncorhynchus kisutch*, in Washington state. His duties involved removing the posterior one-third of the kidney of each salmon, preparing macerated wet mounts for microscopic examination, and enumerating metacercariae. He necropsied >1100 fresh-killed juvenile coho salmon without protective gloves. Most kidney specimens examined were positive for metacercarial cysts of *N. salmincola* and most were heavily infected. The patient recalled the onset of the symptoms at ~1 month after the parasite survey was initiated.

The patient's diet seldom consisted of fish and he did not recall eating fish or other seafood products for several months before infection. He never ate raw fish (sashimi) or dishes containing raw fish (e.g., sushi) or cold smoked salmon. Evidently, infection was initiated by accidental hand-to-mouth ingestion of infectious metacercariae during the 3-month study of coho salmon.

The patient's health improved markedly ~7 days after treatment with praziquantel at 20 mg/kg body weight, three times per day for 1 day. Two months after treatment no fluke eggs were observed on stool examination, and eosinophils were not evident in peripheral blood.

Discussion

This case is the first documentation of nanophyetiasis in humans in the USA that does not implicate the ingestion of raw or undercooked salmonid fishes as the method of transmission. Hand-to-mouth contamination occurred during the handling of naturally infected juvenile coho salmon from rivers and tributary streams of Grays Harbor (WA).

Human infection with *N. salmincola* may cause abdominal discomfort, often associated with nausea and vomiting, increased frequency of bowel movements with acute and chronic diarrhea, peripheral blood eosinophilia, weight loss, and fatigue [2]. Characteristic digenetic trematode eggs in stool specimens are diagnostic. Most of these signs and symptoms correspond with those reported by our patient.

The life cycle of *N. salmincola* begins when eggs are expelled into the intestines of a variety of fish-eating animals (e.g., raccoon, otter, spotted skunk, coyotes, foxes, heron, merganser) and pass out with the feces into water. A miracidium hatches from the egg, penetrates a snail host (usu-

Received 24 March 1989; revised 18 July 1989.

Reprints and correspondence: Dr. Lee W. Harrell, P.O. Box 130, Manchester, WA 98353.

The Journal of Infectious Diseases 1990;161:146–148

0022-1899/90/6101-0031$01.00

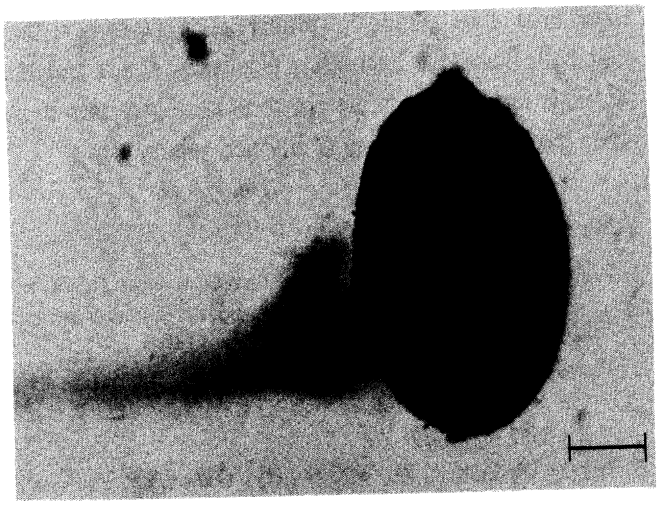

Figure 1. Lugol's iodine-stained bipolar ovum of *Nanophyetus salmincola* (×400; bar = 25 μm).

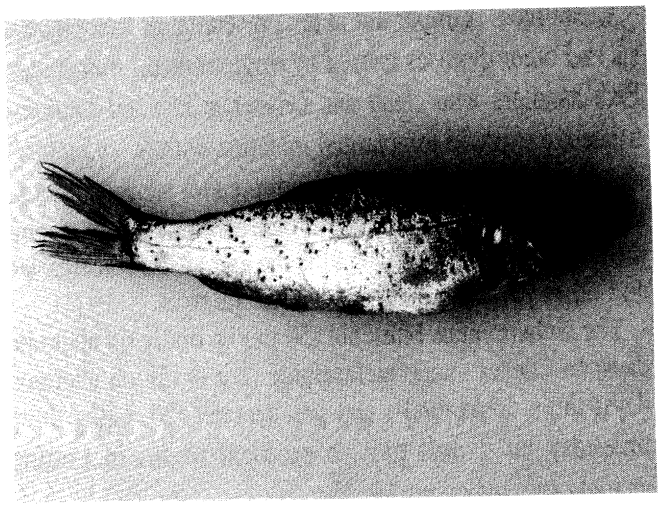

Figure 2. Coho salmon smolt (120 mm) with numerous strikes denoting sites of xiphidiocercarial penetration.

ally *Oxytrema silicula* in the Pacific Northwest), develops, and multiplies. A xiphidiocercaria eventually emerges from the tissues of the snail and penetrates and encysts in the tissues of at least 34 species of fishes; however, salmonid fishes are more susceptible than fishes of other families [4]. Typical strikes indicating xiphidiocercarial penetration of coho salmon smolt are noted in figure 2. When fish (and encysted metacercariae) are eaten by an appropriate piscivorous animal, the fluke matures and the life cycle is completed. Humans become infected by eating the contaminated fish and thus interrupt the trematode's natural life cycle.

Metacercariae may be found in nearly any tissue of coho salmon, but are most numerous in the kidneys, muscles, and fins. Most kidney samples examined during the coho salmon survey were positive for metacercarial cysts, and some samples had >450 per posterior one-third of kidney (figure 3). Thus, the patient was exposed to unusually high numbers of metacercariae for several months. The disease was probably transmitted when he failed to wash his contaminated hands adequately before eating or smoking.

Transmission of parasitic disease via hand contamination has been reported for another species of trematode in the family Troglotrematidae. *Paragonimus westermani* has been reported to infect humans in Japan by contamination of fingers or cooking utensils with the metacercariae during food preparation [5]. Possibly humans may also become infected when they crush rice-eating crabs (intermediate host), splashing themselves with juices of the crab that contain metacercariae [4].

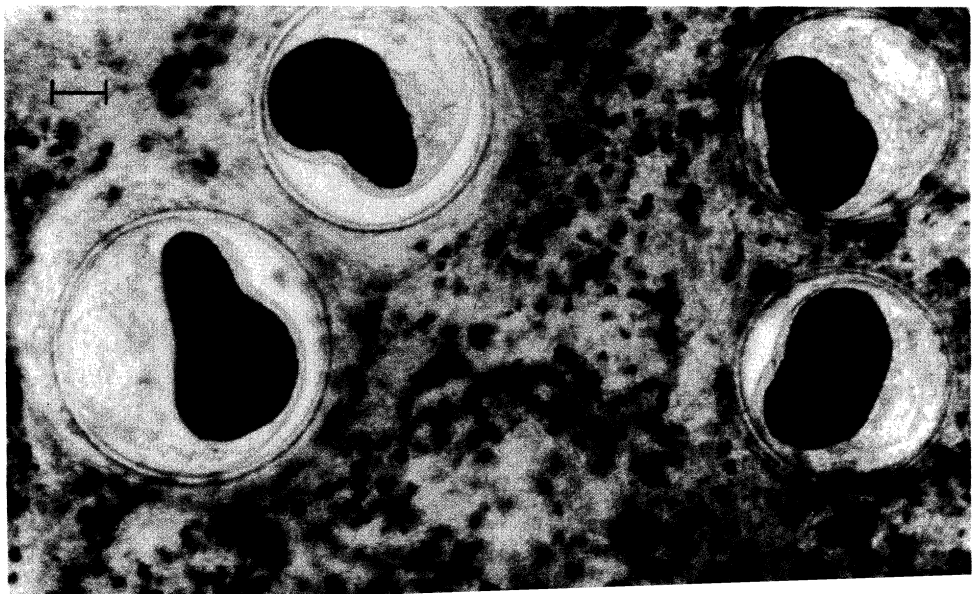

Figure 3. Encysted metacercaria of *Nanophyetus salmincola* in kidney of coho salmon (×100; bar = 100 μm).

Cleanliness is important in the prevention of nanophyetiasis and other diseases caused by troglotrematid trematodes. Fish handlers who clean and eviscerate infected salmonid fishes are exposed to potential infection with *N. salmincola* and, when feasible, should be monitored for signs and symptoms of the disease. Safe disposal of fish viscera is also recommended. Thorough cooking kills the encysted metacercariae and other parasites that might infect humans.

The anthelmintics bithionol (50 mg/kg orally on alternate days; two doses total), niclosamide (2 g orally on alternate days; three doses total), and praziquantel (20 mg/kg three times/day for 1 day) provide excellent results in treating nanophyetus infections [2, 3].

Seven parasitic diseases are known to be transmitted by marine food products in the USA [6]. One of these, plus nanophyetiasis, may expose seafood handlers to increased risk of infection. An adult philometrid nematode infected a Hawaiian fisherman while he filleted a fish [7]. The other six parasitic diseases may result from the consumption of raw or undercooked marine fishes [6].

Nanophyetiasis should be considered in the differential diagnosis of patients with abdominal discomfort, diarrhea, nausea, and vomiting or unexplained peripheral blood eosinophilia, particularly if these patients have a recent history of eating raw or undercooked salmon or trout originating from the enzootic area of the Pacific Northwest [2] or if they have traveled to the Soviet Far East where the disease is also endemic [8]. This report extends the possibilities of infection to include the careless handling of infected salmonids.

References

1. Philip CB. A helminth replaces the usual arthropod as vector of a rickettsia-like disease. In: Proceedings 10th International Congress of Entomology. Ottawa: Mortimer, **1956**;3:651–653
2. Eastburn RL, Fritsche TR, Terhune CA Jr. Human intestinal infection with *Nanophyetus salmincola* from salmonid fishes. Am J Trop Med Hyg **1987**;36:586–591
3. Fritsche TR, Eastburn RL, Wiggins LH, Terhune CA Jr. Praziquantel for treatment of human *Nanophyetus salmincola* (*Troglotrema salmincola*) infection. J Infect Dis **1989**;160:896–899
4. Schmidt GD, Roberts LS, eds. Foundations of parasitology. 2d ed. St. Louis: C. V. Mosby, **1981**
5. Suzuki Z. Epidemiological studies on paragonimiasis in South Izu District, Shizuoka Prefecture, Japan. In: Schmidt GD, Roberts LS, eds. Foundations of parasitology. 2d ed. St. Louis: C. V. Mosby, **1981**:319
6. Deardorff TL. Parasites that are transmitted from marine food products to humans. Int J Food Science Technol (in press)
7. Deardorff TL, Overstreet RM, Okihiro M, Tam R. Piscine adult nematode invading an open lesion in a human hand. Am J Trop Med Hyg **1986**;35:827–830
8. Sinovich LI. Nanophyetosis in the Soviet Far East. In: Proceedings of 10th Conference of Parasitological Problems and Diseases with Natural Reservoirs. Moscow: Acad Nauk SSSR **1959**;2:410–411